



No. 62

# Unsoundnesses and Blemishes of Horses: Feet and Legs

Extension Bulletin E-920

January 1977

*NOTE: The author is Melvin Bradley, Department of Animal Husbandry, University of Missouri. This series of bulletins is reprinted for Michigan use through courtesy of the University of Missouri—Richard Dunn, Extension Specialist in Animal Husbandry, Michigan State University.*

For a discussion of unsoundnesses and blemishes of the head, body, and respiratory tract, and stable vices, see *Extension Bulletin E-921, Unsoundness and Blemishes of Horses: Head, Body, Respiratory Tract and Stable Vices*

Unlike other farm animals, the horse is serviceable only when in motion.

Any abnormal deviation in the structure or action of a horse can render it partly or completely useless. Therefore, any defect that affects serviceability is considered an unsoundness, i.e., lameness, blindness, faulty wind, etc.

Those defects that detract from appearance but do not impair serviceability are considered blemishes, i.e., scars, capped hocks and elbows, etc. Blemishes are looked upon with great disfavor in gaited, parade, and some pleasure horses. They are more common in stock horses and tend to detract from the value less than other types.

An important part of selecting a horse is the ability to recognize common unsoundnesses and blemishes, and faulty conformation that tends to predispose the animal toward unsoundnesses and blemishes. (See *Extension Bulletin E-923, "Leg Set in Horses."*) Some horses become unsound at an early age because of coarse, crooked legs, whereas others remain useful for years. (See *Extension Bulletin E-978* for age determination.) As with automobiles, abusive treatment, excessive use, and poor care will render any horse unsound.

## UN SOUNDNESSES AND BLEMISHES OF THE FEET

The old adage, "No foot, no horse," has much merit. As a major shock-absorbing mechanism the feet are subjected to great stress. Horses that work hard most of their lives may acquire one or more unsoundnesses of the feet to varying degrees as they get older. Wide, deep heels, dense horn, combined with proper care and shoeing, will reduce the chances for these conditions to develop.

**Sidebones (Figure 1).** This is a common unsoundness resulting from wear, injury, or abuse. On each side of the heel extending above the hoof are elastic cartilages just under the skin that serve as part of the shock-absorbing mechanism. They are commonly termed lateral cartilages. When they ossify (turn to bone) they are called sidebones. In the process of ossification they may be firm but movable inward and outward by the fingers. The horse is then considered "hard at the heels." Sidebones are more common to the front outside lateral cartilage than to other locations.



Figure 1. Sidebone

**Ringbone (Figure 2).** Ringbones are not very common but are serious unsoundnesses. These bony deposits usually appear just above the coronary band (hoof head) on a hind foot, although front feet may be affected. The long and short pastern bones may fuse together causing severe pain and lameness.



Figure 2. Ringbone



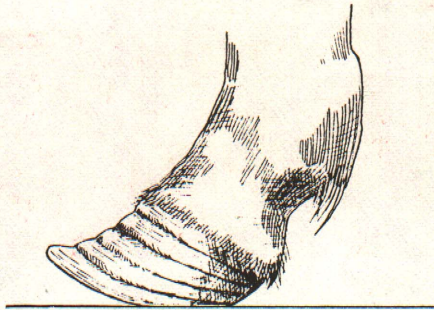


Figure 3. Founder

**Founder (laminitis) (Figure 3)** is an inflammation of the sensitive laminae which attach the hoof to the fleshy portion of the foot. Its cause is probably a sensitization (allergy). When horses gain access to unlimited amounts of grain, founder often results. Other conditions conducive to founder are retained placenta after foaling and sometimes lush grass. All feet may be affected, but front feet usually suffer the most. Permanent damage usually can be reduced or eliminated by immediate attention by a competent veterinarian.

Permanent damage results from dropping of the hoof sole and upturn of the toe walls when treatment is neglected.

**Navicular disease** is an inflammation of navicular bone and bursa. The condition causes lingering lameness and should be diagnosed and treated by a veterinarian.

**Corns** appear as reddish spots in the horny sole usually on the inside of the front feet, near the bars. Advanced cases may ulcerate and cause severe lameness.

There are many causes but bruises, improper shoeing, and contracted feet are the most common. Response to correct treatment and shoeing is usually satisfactory.

**Hoof cracks.** When hoof cracks extend upward to or near the hairline, lameness often results. When well established, the condition is difficult to arrest and cure. It can be prevented in most hooves by proper trimming and shoeing before it becomes serious.

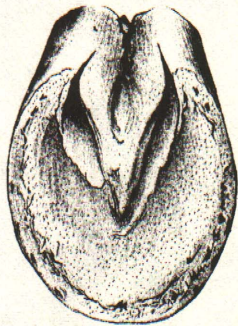

Figure 4. Contracted foot

**Contracted feet (Figure 4)** are a result of continued improper shoeing, prolonged lameness, or excessive dryness, where the heels lose their ability to contract and expand when the horse is in motion. Horses kept shod, those with long feet, and those with narrow heels are susceptible to the condition. Close trimming, going barefooted, or corrective shoeing usually effects sufficient cure to restore the horse to service.

**Thrush** is a filth disease enhanced by decomposition of stable manure around the bars and frog of the foot. It may cause lameness. Response to cleanliness and treatment is usually prompt and complete.

**Scratches or grease heel** is characterized by inflammation and scab formation on the back surfaces of the fetlocks. Prevent as for thrush.

## UNSOUNDNESSES AND BLEMISHES OF THE LEGS

### FRONT LEGS

The front legs bear about 60% of the weight of a horse. Healthy horses stand at rest with weight equally distributed on both front legs. Lameness in the foot or leg, will cause "pointing." *Pointing* refers to a state of rest with one foot positioned about 10 to 12 in. ahead of the other in an effort to reduce weight on the affected side (Figure 5).

Weight is habitually shifted from one hind limb to the other by healthy horses during rest and does not indicate lameness.




Figure 5. Pointing

**Splints (Figure 6)** are bony deposits that appear on the upper inside border of the front cannon. They seldom cause lameness but occasionally a "high" splint may interfere with the action of the knee and cause unsoundness. Young horses stressed by play or training may "blow" a splint. If lameness persists more than a few days, a veterinarian should treat splints.

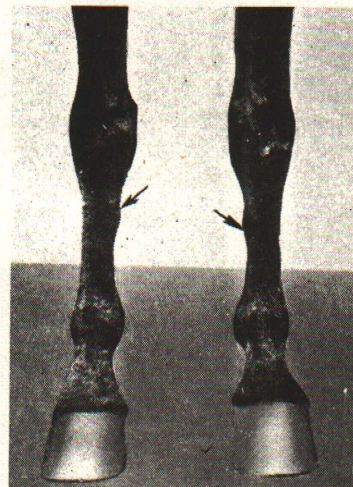


Figure 6. Splints



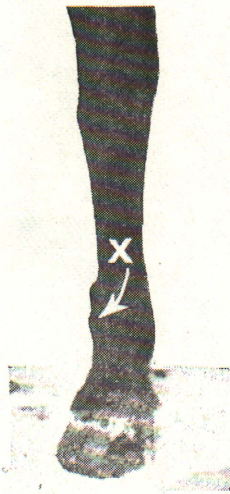


Figure 7. Wind puffs

**Wind or road puffs (Figure 7).** Small swellings around the ankles and lower cannons are common to horses that are used heavily or trailered a lot, or to older animals. Those with adequate flat bone, well-defined joints, and prominent veins usually have sufficient substance and circulation to withstand wear better than horses with coarse, round bone and meaty legs with poorly-defined joints and veins. Puffs are blemishes.

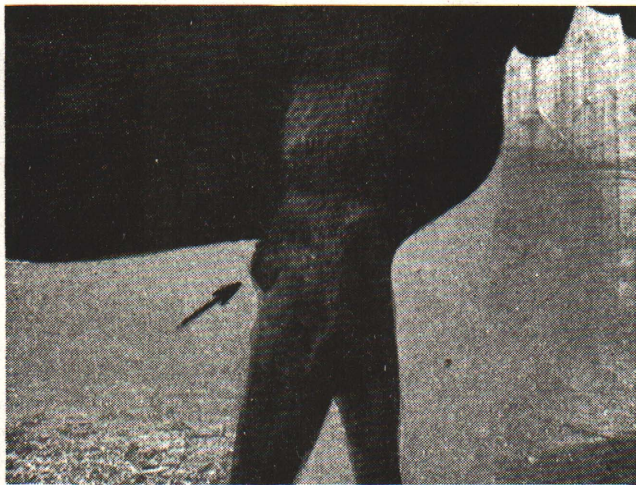

Figure 8. Capped elbow

**Capped elbow** or "shoe boil" (Figure 8) is a blemish at the point of the elbow. It is usually caused by injury from the shoe when the front leg is folded under the body while the horse is lying down. Shoes with calks (heels) cause more damage than plates.

**Bowed tendons (Figure 9)** are apparent by a thickening of the back surface of the leg immediately above the fetlock. One or more tendons and ligaments may be affected, but those commonly involved are the superflexor tendon, deep flexor tendon, and suspensory ligament of one or both front legs. Predisposing causes are severe strain, wear and tear with age, and relatively small tendons attached to light, round bone.

Bowed tendons usually cause severe unsoundness.

## HIND LEGS

The hock is the most vulnerable, therefore the most important, joint of the body. All of the power of a pulling

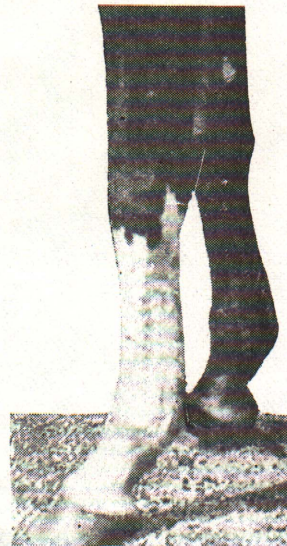


Figure 9. Bowed tendon

horse is generated in the hindquarters and transmitted to the collar by contact with the ground via the hocks. Working stock horses must bear most of the weight on the hind legs by keeping their hocks well under them, if they are to attain maximum flexibility. Degree of finesse is determined with gaited and parade horses by how well they "move" off their hocks.

Structurally sound hocks then should be reasonably deep from top to bottom, well-supported by fairly large, flat, straight bone, be characterized by clean-cut, well-defined ligaments, tendons, and veins; and should be free from induced unsoundnesses and blemishes.

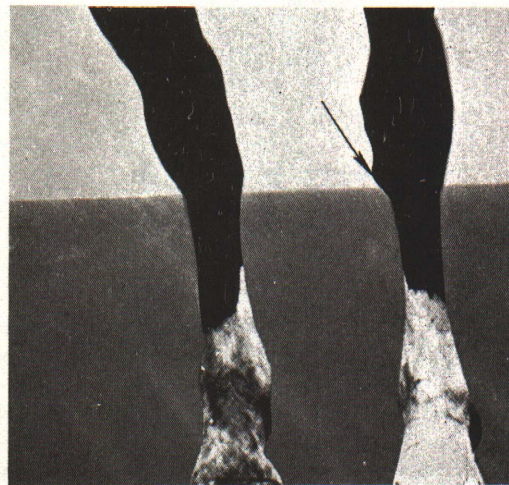

Figure 10. Bone spavin

**Bone or Jack Spavin (Figure 10).** Bone spavins are common unsoundnesses of light horses, especially those with sickle hocks and/or shallow hock joints from top to bottom surmounting fine, round bone. Such conformation should be seriously faulted in a working stock horse.

A bony enlargement at the base and inside back border of the hock may be a bone spavin. Inspect horse by bending or squatting in front of the horse and looking between the front legs at the face of the hocks, or by standing near a front leg and looking under the belly at the opposite hock. Before passing judgment, assume the same position and look at the



opposite hock. If they are both alike, the horse is probably normal. In the early stages, lameness may be apparent only when the horse has remained standing for awhile. Bone spavins, like ringbones, may fuse bones and render joints inarticulate.

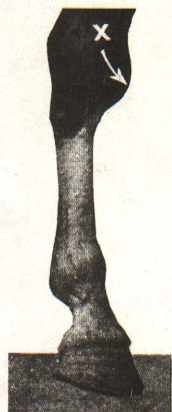

Figure 11. Bog spavin

**Bog Spavin and Thoroughpin (Figure 11).** Bog spavins are soft swellings on the inside-front area of the hocks that may result from the presence of synovial fluid ("joint oil"). Blemishes of this type are more common to heavy horses than light ones, although individuals of low quality are susceptible to the condition.

Thoroughpins are blemishes that appear as soft swellings above and back of the hock joint just in front of the large tendon. They can be pressed from side to side, hence the name.

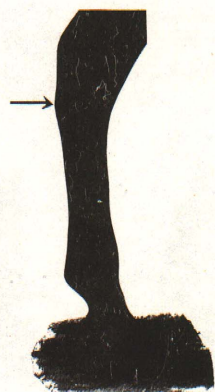


Figure 12. Curb

**Curbs (Figure 12).** Curbs can be seen best from a side view. They appear as swellings on the back border of the base of the hock. They result from inflammation and thickening of the sheath of one of the important tendons. Shallow, sickle hocks predispose to development of curbs. They may or may not cause lameness.

**Capped Hock (Figure 13).** A thickening of the skin or large callus at the point of the hock is a common blemish. Many capped hocks result from bumping the hocks when trailering in short trailers or with unpadded tail gates.

**Stringhalt (Figure 14)** or crampiness of the hind leg (s), is a disease of the nervous system resulting in spasmodic flexion of one or both hocks when the horse is first moved after standing or when caused to back. The hock is raised abnormally high.

It occurs more frequently in older animals and may not render the animal unserviceable.



Figure 13. Capped hock

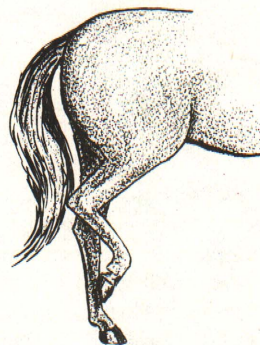


Figure 14. Stringhalt

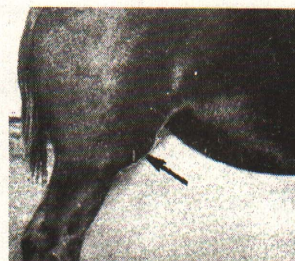

Figure 15. Stifle

**Stifled (Figure 15).** When the patella of the stifle joint is displaced, the animal is stifled. If the patella is displaced outward, severe lameness results. If it is displaced inward, lameness is less serious and sudden movement may replace it; however, the condition is likely to recur frequently.

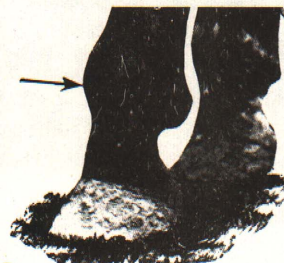


Figure 16. Cocked-ankle

**Cocked-Ankles (Figure 16).** Cocked ankles may appear in front but are more common to hind legs. Severe strain or usage may result in inflammation and/or shortening of the tendons and a subsequent forward position of the ankle joints. Advanced cases impair movement and decrease usefulness.