

Michigan State University Extension

Porcine Proliferative Enteritis

(Intestinal adenomatosis, necroproliferative enteropathy, proliferative ileitis)

Authors

Robert Glock, Colorado State University
Harold Kurtz, University of Minnesota
Larry Lomax, Midland, Michigan
H. Leon Thacker, Purdue University

Reviewers

Duane Miksch, University of Kentucky
Bert and Sandy Ramsay, Westover, Maryland
David and Linda Sargent, Swan Valley, Idaho
David Reeves, University of Georgia

Proliferative enteritis can occur in any pig past weaning age. The disease is named because a constant observation at necropsy is a thick-walled distal small intestine or occasionally large intestine, and proliferation (increased numbers) of crypt epithelial cells is observed upon microscopic examination of tissue specimens from the affected intestine. The first symptom in affected pigs is diarrhea which may contain blood.

Prevalence

Proliferative enteritis can affect pigs of any age past weaning but is most commonly observed in 40 to 100 lb feeder pigs, bred gilts, sows, and boars and occasionally in finishing hogs. The disease occurs in both indoor and outside swine raising facilities throughout the United States, and throughout the year. Generally 1 to 10% (rarely up to 30%) of bred gilts, sows, boars, or finishing hogs are affected. Up to 50% of feeder pigs may be affected; however, usually only 1 to 10% are affected. It is not unusual on some farms to have sporadic cases throughout the year with periodic sudden increases in the number of pigs affected. The death rate is extremely variable.

Clinical Signs

Feeder pigs have persistent or intermittent diarrhea for several days to weeks. The feces are soft to fluid and yellow to dark brown. Blood-tinged feces and/or feces with flecks of yellow fibrin also may be observed. Feeder pigs lose weight and eventually appear stunted and emaciated. Affected pigs usually continue to eat and drink but at a reduced rate. A few sows, boars, and finishing hogs may have similar clinical signs. However, more frequently, they have loss of appetite for 1 to 3 days before they begin to pass soft to watery and bright red to black feces which may contain mucus. Death often follows within 24 to 72 hours after the onset of hemorrhagic (bloody)

diarrhea. Loss of body weight or condition is not usually a feature in older swine.

Postmortem

The characteristic lesion at necropsy (postmortem examination) is a thick-walled distal jejunum and ileum (small intestine) (Fig. 1). The cecum and proximal colon (beginning of the large intestine) may be similarly affected. When the affected intestine is opened, the lumen (passageway) usually contains any combination of clotted blood, yellow pseudomembranes (aggregates of fibrin and dead cellular debris adhering to the mucosal surface), or unclotted blood (Fig. 1). Removal of this material reveals a demonstrably thick and red mucosal surface. Feeder pigs tend to have less blood and more fibrin and necrotic (dead cells) material in the intestinal lumen while older swine tend to have more blood present.

Cause

Epithelial cells in the thickened mucosa consistently contain small, curved rod-shaped bacteria. These were incorrectly identified as various *Campylobacter* spp. Evidence now indicates that they are members of a different genus and that they cannot yet be cultured in artificial media in the absence of living cells. They have not yet been definitively named.

Diagnosis and Differential Diagnoses

Proliferative enteritis is diagnosed by gross and microscopic examination of the intestinal lesions. A thick ileum with either fibrinous exudate or blood in the lumen is a usual finding at necropsy. However, in some cases lesions are mild and require microscopic evaluation. The demonstration of curved rod-shaped bacteria in tissue sections of proliferative mucosal

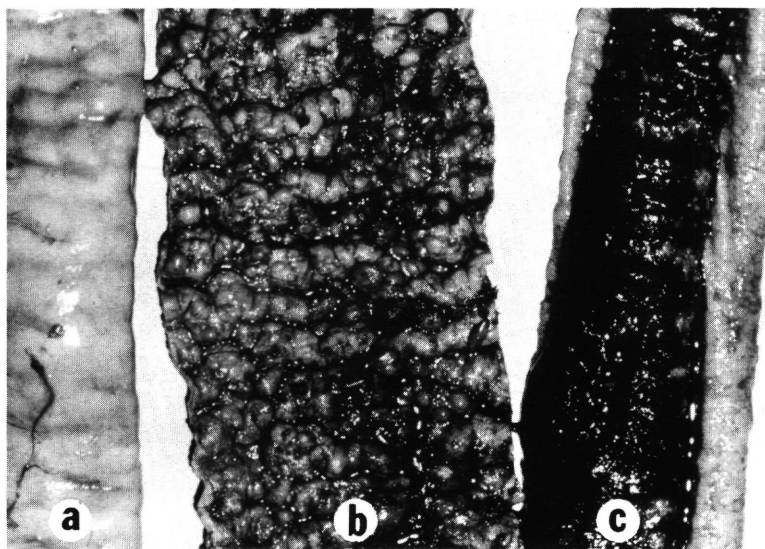


Figure 1. Small intestine (ileum) from gilt with proliferative enteritis. The ileal wall (a) is thick. The ileal lumen (passageway) contains a fibrin and dead cellular pseudomembrane (b) and clotted blood (c).

epithelial cells is a diagnostic aid. Silver stains are frequently used to demonstrate typical bacteria. Isolation of *Campylobacter* species organisms from affected intestinal tissue by bacteriologic techniques is not useful. More specific tests are in the developmental stages.

Differential diagnoses include salmonellosis, swine dysentery, whipworms, poisoning by mold toxins, anticoagulant or caustic chemical ingestion, gastric ulcers, torsion (twisting) of the mesentery, and intestinal hemorrhage of unknown cause. Intestinal hemorrhage of unknown cause is a condition where the wall of the small intestine is either normal or thin and the lumen is filled with either clotted or unclotted blood. At present, the exact cause of this condition is unknown.

Treatment and Control

Proliferative enteritis has been observed in swine, especially feeder pigs and adults, 1 to 4 weeks after movement on the same premise or after introduction of new stock into the herd. At present, there are no effective means to detect infected animals not showing clinical signs. Consequently, necropsies must be performed and an accurate laboratory diagnosis determined before the disease can be recognized. Treatment of proliferative enteritis has been conducted on an observation basis only, and controlled field studies are needed. The use of antibiotics in feed or water has given variable results. Tetracyclines at therapeutic levels have been used with success. A wide variety of other antibiotics including neomycin, tylosin, bacitracin, and virginiamycin also have been used at therapeutic levels.

Treatment (antibiotic in feed or water for 1 to 3 weeks) has been most successful in feeder pigs when the disease was diagnosed before pigs became stunted and emaciated. However, adult swine and finishing hogs that had hemorrhagic diarrhea have proven difficult to treat successfully. Further occurrence of the clinical disease has been reduced in adult

swine and finishing hogs when antibiotics have been given for 1 to 3 weeks. A vaccine is not available.

Since reliable detection of infected, but not clinically ill, swine is not currently possible, no absolute prevention methods can be offered. Practices of good sanitation; avoidance of overcrowding; quarantine and perhaps antibiotic therapy to recently purchased animals; and minimizing stress, especially during times when animals are moved from one enclosure to another on a farm, are recommended.

Summary

Proliferative enteritis is a swine intestinal disease consistently associated with typical intracellular organisms. The disease affects all ages of swine past weaning and occurs throughout swine-raising areas in the United States. Presumptive diagnosis is made at necropsy by observing a thick-walled distal small intestine which usually contains blood or yellow exudates. The diagnosis is confirmed microscopically in the laboratory by observing typical intracellular organisms in intestinal proliferative epithelial cells. Treatment with various antimicrobial agents has had varied success. No absolute preventive measures are currently available.

Reference to products in this publication is not intended to be an endorsement to the exclusion of others which may be similar. Persons using such products assume responsibility for their use in accordance with current directions of the manufacturer.

The information represented herein is believed to be accurate but is in no way guaranteed. The authors, reviewers, and publisher assume no liability in connection with any use for the products discussed and it makes no warranty, expressed or implied, in that respect, nor can it be assumed that all safety measures are indicated herein or that additional measures may be required. The user, therefore, must assume full responsibility, both as to persons and as to property, for the use of these materials including any use which might be covered by patent.