

COOPERATIVE EXTENSION SERVICE

• MICHIGAN STATE UNIVERSITY

Porcine Proliferative Enteritis

(Intestinal adenomatosis, necroproliferative enteropathy, proliferative ileitis)

Authors

Larry Lomax, University of Georgia
Robert Glock, Casa Grande, Arizona
Harold Kurtz, University of Minnesota
Leon Thacker, Purdue University

Reviewers

Duane Miksch, University of Kentucky
Bert Ramsay, Westover, Maryland
David D. Sargent, Swan Valley, Idaho
James R. Wadsworth, University of Vermont

Proliferative enteritis can occur in any pig past weaning age. The disease is so named because a constant observation at necropsy is a thick-walled distal small intestine or occasionally large intestine, and proliferation (increased numbers) of crypt epithelial cells is observed upon microscopic examination of tissue specimens from the affected intestine. The first sign in affected pigs is diarrhea which may contain blood.

Prevalence

Proliferative enteritis can affect pigs of any age past weaning but is most commonly observed in 40-100 lb. feeder pigs, bred gilts, sows, and boars. Some farms may also find the disease in finishing hogs. The disease occurs in both confinement and conventional swine raising facilities, in areas throughout the United States, and throughout the year. Generally 1-10% (rarely up to 30%) of bred gilts, sows, boars, or finishing hogs are affected. Up to 50% of feeder pigs may be affected; however, usually 1-10% are affected. It is not unusual on some farms to have sporadic cases throughout the year with periodic sudden increases in the number of pigs affected. The death rate is extremely variable.

Clinical Signs

Feeder pigs have persistent or intermittent diarrhea for several days to weeks. Their feces are soft to fluid and are yellow to dark brown. Blood-tinged feces and/or feces with flecks of yellow fibrin may also be observed. Feeder pigs lose weight and eventually appear stunted and emaciated. Affected pigs usually

continue to eat and drink but at a reduced rate. A few sows, boars, and finishing hogs may have similar clinical signs. However, far more frequently, they have loss of appetite for 1 to 3 days before they begin to pass soft to watery and bright red to black feces which may contain mucus. Death often ensues within 24 to 72 hours after the onset of hemorrhagic (bloody) diarrhea. Loss of body weight or condition is not usually a feature in older swine.

Postmortem

The characteristic lesion at necropsy (postmortem examination) is a thick-walled distal jejunum and ileum (small intestine) (Fig. 1). The cecum and proximal colon (beginning of the large intestine) may be similarly affected. When the affected intestine is opened, the lumen (passageway) usually contains any combination of clotted blood, yellow pseudomembranes (aggregates of fibrin and dead cellular debris adhering to the mucosal surface), or unclotted blood (Fig. 1). Removal of this material reveals a demonstrably thick and red mucosal surface. Feeder pigs tend to have less blood and more fibrin and necrotic (dead cells) material in the intestinal lumen while older swine tend to have more blood present.

Cause

Epithelial cells in the thickened mucosa consistently contain small, curved rod-shaped bacteria. This agent has been identified as a member of the genus *Campylobacter*. More specifically, two agents from this genus, *Campylobacter sputorum* subspecies *mucosalis* and *Campylobacter hyointestinalis*, have

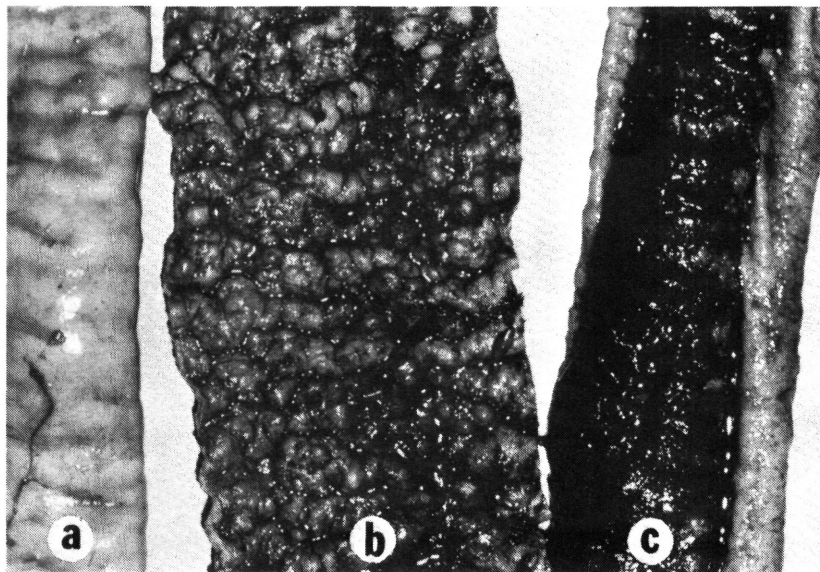


Figure 1. Small intestine (ileum) from gilt with proliferative enteritis. The ileal wall (a) is thick. The ileal lumen (passageway) contains a fibrin and dead cellular pseudomembrane (b) and clotted blood (c).

been associated with the disease. Experimentally, *C. sputorum* subspecies *mucosalis* in pure culture will produce proliferative lesions in the ileum. However, the various natural evidences of the disease have not been totally reproduced experimentally. Other factors or microbial agents may be necessary to produce the typical clinical disease.

Diagnosis and Differential Diagnoses

Proliferative enteritis is diagnosed by gross and microscopic examination of the intestinal lesions. A thick ileum with either fibrinous exudate or blood in the lumen are usual findings at necropsy. However, in some cases lesions are mild and require microscopic evaluation. The demonstration in tissue sections of *Campylobacter* species-like organisms in proliferative mucosal epithelial cells is diagnostic. Silver stains are frequently used to demonstrate *Campylobacter* species. Isolation of *Campylobacter* species organisms from affected intestinal tissue by bacteriologic techniques should be attempted but is not always rewarding.

Differential diagnoses include salmonellosis, swine dysentery, whipworms, poisoning by mold toxins, anticoagulant or caustic chemical ingestion, gastric ulcers, torsion (twisting) of the mesentery, and intestinal hemorrhage of unknown cause. Intestinal hemorrhage of unknown cause is a condition where the wall of the small intestine is either normal or thin and the lumen is filled with either clotted or unclotted blood. At present, the exact cause of this condition is unknown.

Treatment and Control

Proliferative enteritis has been observed in swine, especially feeder pigs and adults, 1 to 4 weeks after movement on the same premise or after introduction of new stock into the herd. At present, there are no effective means to detect infected animals not showing clinical signs. Consequently, necropsies must be performed and an accurate laboratory diagnosis determined before the disease can be recognized. Treatment of proliferative enteritis has been conducted on an observation basis only, and controlled field

studies are needed. The use of antibiotics in feed or water has given variable results. Tetracyclines at therapeutic levels have been used with success. A wide variety of other antibiotics including neomycin, nitrofurazone, tylosin, and bacitracin also have been used at therapeutic levels.

Treatment (antibiotic in feed or water for 1 to 3 weeks) has been most successful in feeder pigs when the disease was diagnosed before pigs became stunted and emaciated. However, adult swine and finishing hogs that had hemorrhagic diarrhea have proved difficult to treat successfully. Further occurrence of the clinical disease has been reduced in adult swine and finishing hogs when antibiotics have been given for 1 to 3 weeks. A vaccine is not available.

Since reliable detection of infected, but not clinically ill, swine is not currently possible, no absolute prevention methods can be offered. Practices of good sanitation; avoidance of overcrowding; quarantine and perhaps antibiotic therapy to recently purchased animals; and minimizing stress, especially during times when animals are moved from one enclosure to another on a farm, are recommended.

Summary

Proliferative enteritis is a swine intestinal disease consistently associated with *Campylobacter* species organisms. The disease affects all ages of swine past weaning and occurs throughout swine-raising areas in the United States. Presumptive diagnosis is made at necropsy by observing a thick-walled distal small intestine which usually contains blood or yellow exudates. The diagnosis is confirmed microscopically in the laboratory by observing *Campylobacter* species-like organisms in intestinal proliferative epithelial cells. Treatment with various antimicrobial agents has had varied success. No absolute preventive measures are currently available.

Reference to products in this publication is not intended to be an endorsement to the exclusion of others which may be similar. Persons using such products assume responsibility for their use in accordance with current directions of the manufacturer.
