

# pork industry handbook

FILE COPY  
DO NOT REMOVE

Michigan State University Extension

## Internal Parasites in Swine

### Authors

T. Bonner Stewart, Louisiana State University  
Bert E. Stromberg, University of Minnesota  
D. Bruce Lawhorn, Texas A & M University

### Reviewers

James and Annette Bellm, Carlinville, Illinois  
LeRoy G. Biehl, University of Illinois  
Ralph F. Hall, University of Tennessee  
Steve and Sharon Oetting, Concordia, Missouri

Internal parasitism in swine has been estimated to cause an annual loss of \$538 million (\$ value of 1984). This estimate includes losses caused from death, condemnation, reduction in performance and cost of dewormers. However, this does not include losses to pneumonia, neonatal diarrhea and other conditions in which parasites may be involved.

Internal parasites in the stomach, intestines and other organs compete directly for food, thereby reducing the pig's growth rate and feed efficiency. Also, tissue injury caused by migrating worms helps the establishment of other disease-producing organisms such as *Serpulina hyodysenteriae* and *Mycoplasma hyopneumoniae*.

The purpose of this fact sheet is to describe the internal parasites in swine, their life cycles and the management practices and products necessary to control them.

### Roundworms

All dewormers placed on the market for swine during the past 30 years have been very effective against the large roundworm (*Ascaris suum*). Even so, it is still the common parasite of swine. The large roundworm is the largest worm infecting pigs in the United States. It is about 12 inches (30.5 cm) in length and the diameter of a pencil (Figures 1 and 1a). The adults are found primarily in the small intestine but also may be found in the stomach or bile duct. The female ascarid produces large numbers of eggs (as many as one million/day) which pass out in the feces. The eggs have a thick, rough shell which provides protection from adverse environmental conditions (Figure 5c). These features also enable easy identification. Eggs require about four weeks to develop to the infective stage under ideal conditions. Eggs in fresh manure are not infective.

The pig is infected by ingestion of the infective eggs, which hatch in the small intestine releasing larvae which

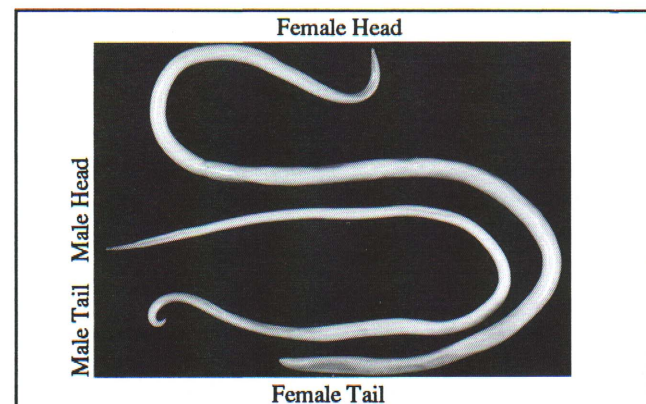


Figure 1. Roundworm (*Ascaris suum*). The large one is the female, the small one with curled tail is the male.

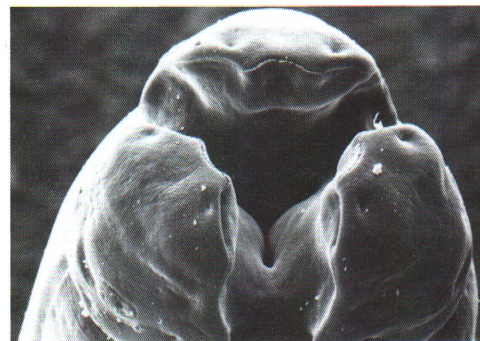

Figure 1a. Electron micrograph of the mouth and lips of the large roundworm (*Ascaris suum*). Note the rows of teeth on the lips edges and the two small pits on each of the three lips containing sensory organs. These worms graze along the small intestinal mucosa.

penetrate the intestinal wall. These larvae utilize the circulatory system to migrate to the liver. The larvae migrate through the liver and again use the circulatory system to continue their migration to the lungs. They break out of the alveolar capillaries into the airspace where they travel up the bronchial tree, the trachea, and then they are coughed up and reswallowed. Once in the small intestine, they continue their development to adult worms. Egg laying begins in about six to eight weeks after infection.

When large numbers of larvae migrate through the liver, they cause localized hemorrhages and scarring. These are later replaced with connective tissue which appears as white spots on the surface and throughout the liver (Figure 2). These white spots are called milk spots and are responsible for liver condemnation. Milk spots develop more rapidly on subsequent infections and are immune mediated as a result of host reaction. These lesions regress and the liver appears normal in about seven weeks.

Larvae that escape entrapment in the liver migrate to the lungs where they cause petechial (very small or minute) hemorrhages when they break into the air space. This may lead to verminous pneumonia and results in a cough. Pigs are more susceptible to secondary bacterial or viral infections during the parasite's lung migration. Immunity develops subsequent to infection. The level of immunity increases according to the number of larvae trapped in the liver and lungs.

## Nodular Worms

Nodular worms (*Oesophagostomum spp.*) are very common in adult pigs throughout the United States. Adults, about 1/2 inch (1.3 cm) in length, are found in the large intestine (Figures 3 and 3a). Typical strongyle type eggs (Figures 5d and 5e) are passed in the feces; they hatch and develop into infective larvae in about one week, and can survive for 12 months in protected areas.

Infective larvae are ingested and penetrate the mucosal lining of the large intestine, causing small nodules. Most return to the lumen or cavity of the intestine in about one week and develop to adults and begin laying eggs in about five weeks. The adults cause little harm; however, the pea-sized nodules caused by the larvae are thought to interfere with intestinal absorption. Severe infections can result in excessive weight loss and contribute to the "thin sow syndrome" during lactation. Nodules generally disappear within five weeks.

## Whipworm

The swine whipworm (*Trichuris suis*) is present throughout the United States. The adult worms may be up to two inches (5 cm) in length, with the anterior two-thirds of the body thin and whip-like and the posterior one-third like the whip handle (Figures 4 and 4a). The adults are found in the large intestine and the typical football-shaped eggs (Figure 5f) are passed in the feces. These eggs require about three weeks to reach the infective stage in the environment and must be ingested to continue the infection. The eggs are ingested and hatched, and then the larvae penetrate into the intestinal wall. They remain in the mucosa (membrane lining the intestine) for two weeks, emerge from the mucosa in the third week and develop into adults while attached to the cecum and large intestinal mucosa.

Large numbers of worms may cause inflammation and result in diarrhea, dehydration, anorexia and even death. Young animals are primarily affected; the diarrhea may resemble bloody dysentery. The thick-shelled eggs remain viable in

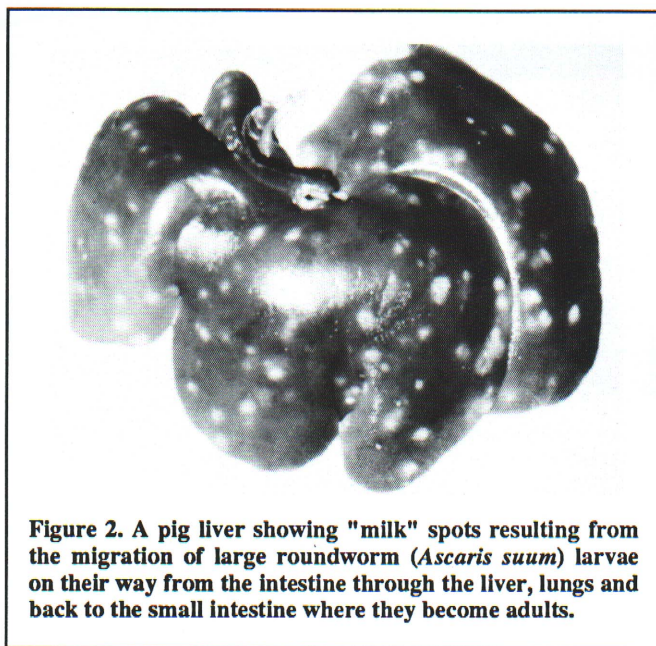


Figure 2. A pig liver showing "milk" spots resulting from the migration of large roundworm (*Ascaris suum*) larvae on their way from the intestine through the liver, lungs and back to the small intestine where they become adults.




Figure 3. Nodular worm (*Oesophagostomum sp.*). The large one is the female, the small one with enlarged tail is the male.

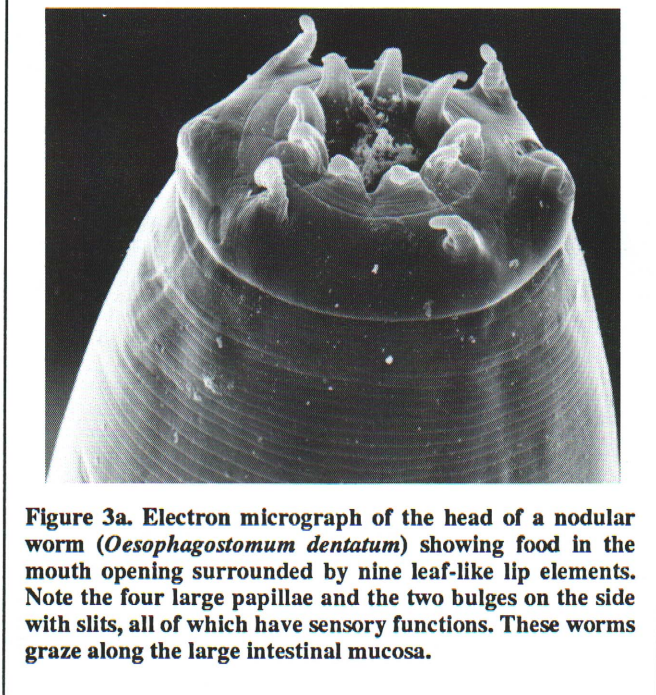


Figure 3a. Electron micrograph of the head of a nodular worm (*Oesophagostomum dentatum*) showing food in the mouth opening surrounded by nine leaf-like lip elements. Note the four large papillae and the two bulges on the side with slits, all of which have sensory functions. These worms graze along the large intestinal mucosa.

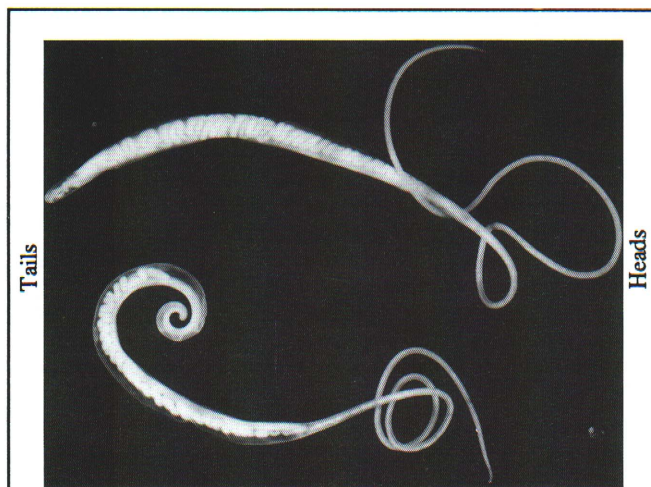


Figure 4. Adult whipworm (*Trichuris suis*). The large one is the female, the small one with curled tail is the male.

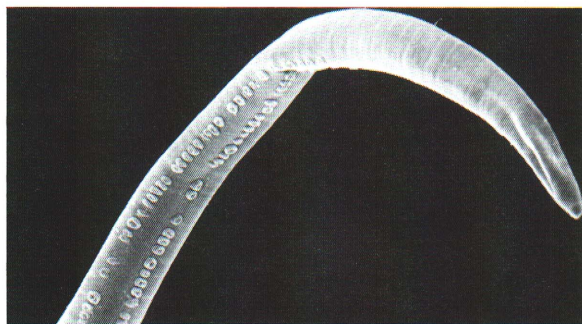


Figure 4a. Electron micrograph of the anterior "whip" end of the whipworm (*Trichuris suis*). The double row of structures are gland openings located in the area which becomes attached to the large intestinal mucosa allowing the head to move freely in search of food. A small spear-like lancet just inside the mouth is protrusible and used to penetrate tissues. Whipworms feed on body fluids including blood.

the environment for extended periods of time (up to 6 years) and are most frequently available to animals that have access to pasture.

### Threadworms

Intestinal threadworms (*Strongyloides ransomi*) are less than 1/4 inch (6.35 mm) long, and they are embedded in the surface of the small intestine. Threadworm infections are most frequently found in warmer climates, primarily in the southeastern United States and are rarely encountered in the North Central states. Thin shelled, ellipsoidal eggs (Figure 5a) pass in the feces, hatch and develop to the infective larval stage on the ground. Infection is via penetration of the skin or oral mucosa.

The route of migration is thought to be via the circulatory system to the lungs, up the bronchial tree and swallowed. A considerable number of larvae migrate to the mammary glands, where they become dormant. Those migrating to the intestine develop to adults (parthenogenic females capable of reproduction without males), begin to lay eggs about one week after infection and generally cause little tissue damage.

The dormant larvae become activated in the lactating sow and infect the nursing piglets via the colostrum. These larvae mature in four days and may cause severe damage when there are large numbers of worms. This may result in a severe diarrhea in piglets during the first 14 days which can be confused with bacterial scours. Mortality may be as high as 75 percent and those that survive may be stunted and feed conversion may be poor.

### Stomach Worms

The red stomach worm (*Hyostromylus rubidus*) is up to 3/8 inch (9.5 mm) in length, red in color (due to ingested blood) and found in the stomach. They are found throughout the United States, primarily in swine on pasture. Eggs passed in the feces develop to infective larvae in about one week. After ingestion, the larvae enter the stomach mucosa or lining, emerge in about two weeks and develop into egg laying adults in about three weeks post-infection.

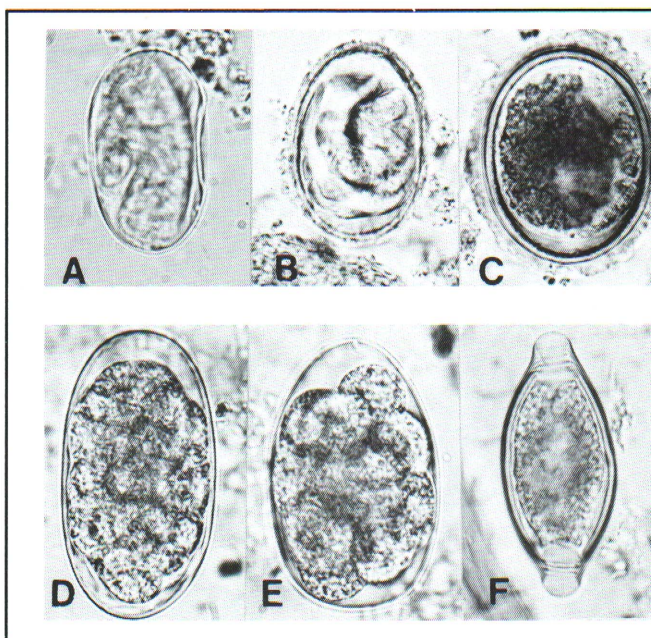


Figure 5. Eggs of common pig internal parasites found in fresh manure. All photomicrographs were taken at the same magnification (X400).

5a. *Strongyloides ransomi*, intestinal threadworm eggs are thin-shelled and are in the larval stage when passed.

5b. *Metastrongylus spp.*, lungworm eggs have rough thick shells. They look very much like the ascarid eggs (c) but are smaller, lighter in color, and are in the larval stage when passed.

5c. *Ascaris suum*, large roundworm eggs have rough thick shells, are dark yellow or brown, and are in the one cell stage when passed.

5d and 5e. *Oesophagostomum spp.* nodular worm and *Hyostromylus rubidus*, stomach worm eggs are multicellular. The eggs are ellipsoidal with relatively thin, smooth shells. They vary in size and shape, are in the 8-32 cell stage, and brown in color when passed.

5f. *Trichuris suis*, whipworm eggs are easy to recognize by their football-like shape and end plugs, thick smooth shell, and dark yellow color. They are in the one cell stage when passed.

The presence of a large number of larvae and adults can produce anemia and stomach inflammation. Incidence of the stomach worm has decreased due primarily to life cycle rearing in modern facilities. Eggs are typical strongyle type and difficult to distinguish from *Oesophagostomum spp.* (Figures 5d and 5e).

## Lungworms

Lungworms (*Metastrongylus spp.*) are most prevalent in the Midwest and the Southeast and require an earthworm intermediate host to complete their life cycle. The adult worms are almost 2 inches (5 cm) in length and lie in the bronchi and bronchioles. The eggs are coughed up, swallowed and passed in the feces (Figure 5b). An earthworm must ingest these eggs for development to progress.

The earthworm with the infective larvae is ingested by the pig. Larvae are freed upon digestion, enter the lymphatics and migrate to the right part of the heart and lungs, where they mature in the airspace. Clinical disease usually occurs with heavy infections and is caused by the tiny hemorrhages caused by migrating larvae, or when adults may obstruct the airways.

Lungworm infection may predispose the animal to respiratory infection due to influenza, mycoplasma or other bacterial pathogens. Control is best accomplished by keeping pigs from earthworms. The incidence of lungworm infection has decreased with inside pig production.

## Kidney Worms

The swine kidney worm (*Stephanurus dentatus*) is present in the Southeastern states and the lower Midwest. It has been introduced and survives in an isolated area of Canada. The worms are 1 to 1 1/2 inches (2.5 to 3.8 cm) in length and lie encysted in pairs along the ureters leading from the kidneys to the bladder. They also can be found in other locations in and around the kidneys.

Adult females produce eggs that are released through openings into the ureters and passed out in the urine. Eggs develop on the ground, hatch and become infective larvae in about one week. Infection is by penetration of skin or by ingestion. Ingested larvae enter visceral lymph nodes and then move to the liver in about 10 to 32 days where they migrate and develop for several months. Fetuses may become infected by errant migrating larvae in gestating sows. The prolonged migration in the liver causes permanent damage that results in condemnation of a large percentage of swine livers, a condition most often occurring in animals from the Southeastern states.

Eventually the worms leave the liver as young adults, reach the kidney area and become sexually mature. Worms frequently can be found in other organs, or in the spinal column where their presence has been shown to cause posterior paralysis in sows. Larvae can develop into egg-laying adults as early as six months after ingestion by a pig; however, it may take nine to sixteen months before eggs are found in the urine.

## Coccidia

Coccidiosis is a very important disease in nursing pigs raised inside. The disease is caused by the protozoan parasite *Isospora suis* and occurs in nursing pigs between five and fifteen days of age. Infected pigs usually develop a yellowish diarrhea that can become very fluid. The pigs continue to nurse

yet become dehydrated and debilitated. Affected pigs are unresponsive to antibacterial therapy. Mortality rate may be moderate but may be increased with concurrent bacterial, viral or parasitic infections.

There is no FDA approved treatment for coccidiosis. Prevention by strict sanitation of farrowing quarters and equipment is strongly recommended. See PIH-81, Swine Coccidiosis.

## *Trichinella spiralis*

Trichinosis is a disease of man and other animals caused by a tiny parasitic worm, *Trichinella spiralis*. Both domestic pigs and wild pigs can become infected with the parasite. For more information see PIH-103, Trichinosis.

## Parasite Control Program

Worm infections with one or more species occur in 80% to 90% of U.S. swine herds, although most producers indicate that they deworm their hogs an average of 1.8 times during a production cycle. Thirty-seven million pounds (16.78 million kg) of liver were condemned in 1986 by USDA inspectors from 78 million hogs slaughtered. Most livers are condemned because of white spots caused by migration of immature worms (larvae). The percent of livers condemned has steadily increased from 13% in 1976 to 16% in 1986. The high rates of liver condemnation in the Southeastern states (45% to 78%) are caused largely by kidney worms and that in the other states (12%) by ascarid larvae.

To effectively reduce the worm population in a swine herd and prevent condemnation losses, several management practices must be used along with dewormers. A good parasite control program will incorporate sound feeding and sanitation practices aimed at prevention of worm infections. Adequate nutrition, especially in regard to protein and vitamin levels is important in protecting pigs against effects of parasitism. Manure removal and thorough cleaning practices during the production cycle are essential in preventing reinfection.

Worm parasites have enormous reproductive potentials. The eggs of ascarids and whipworms have thick shells which protect the infective larvae inside. Larvae can survive in the egg for six years as long as the egg is not exposed to direct sunlight, high temperatures, or allowed to dry completely. The eggs actually survive better when exposed to some disinfectants used on the farm to kill bacteria and other infectious organisms because their use prevents the organisms from attacking the worm egg shells. One of the best methods of preventing transmission of ascarids and whipworms in contaminated quarters is to thoroughly clean equipment, floors and walls to remove all debris. This should be followed with a steam cleaner (steam and detergent) to reach into cracks, crevices and pores of all surfaces. Exposed concrete and wood need special attention because of their porous nature.

Knowledge of the life cycles of the worm species present in a herd will help in planning an appropriate control program. Effective programs will vary with the type of operation. Pigs raised on pasture, dirt lots or dirty concrete floors will need a more rigorous program because pigs will be constantly exposed to infective worm stages compared to pigs raised inside on slotted floors.

Before deciding on a worm treatment and control program, get an accurate diagnosis of the worm species present in the herd. Collect fresh fecal samples from several pigs in each

size group during each production cycle and have your veterinarian or a laboratory examine a composite sample from each group for worm eggs. Carcass and viscera checks of slaughter pigs by your veterinarian can be very helpful in identifying parasite problems.

## Dewormers

No single dewormer is effective against all species of worms (Table 1). The dewormer(s) chosen must be effective against the worms present and it must be given at the proper time for the maximum effect. The spectrum of efficiency, method of delivery, and cost should be considered for best economic results.

All except thiabendazole are effective against the two most common worms of swine, the ascarid (*Ascaris suum*) and nodular worms (*Oesophagostomum spp.*) Dichlorvos is given in either a 1 or 2 day feeding. Fenbendazole can be given in feed for 3 to 12 days, piperazine and levamisole can be given in either feed or water for 1 day, and ivermectin in a single injection. Hygromycin is fed continuously and pyrantel tartrate continuously or in one feeding only. Continuous feeding of either one prevents infection with ascarids and nodular worms and in the case of hygromycin, whipworms (*Trichuris suis*) also.

Fenbendazole is effective against the immature stages of both ascarids and whipworms and can be useful in preventing

further contamination of lots and pastures by deworming pigs every 6 weeks, before females of either parasite can begin producing eggs.

Ivermectin is the only dewormer also effective against the ectoparasites. Injecting sows 10 to 14 days before farrowing prevents transmission of threadworm (*Strongyloides ransomi*) larvae in the colostrum and clears the sow from mange mites that normally are acquired by the suckling pigs while nursing.

Reference to products in this publication is not intended to be an endorsement to the exclusion of others which may be similar. Persons using such products assume responsibility for the use in accordance with current directions of the manufacturer.

The information represented herein is believed to be accurate but is in no way guaranteed. The author, reviewers and publisher assume no liability in connection with any use for the products discussed and it makes no warranty, express or implied, in that respect, nor can it be assumed that all safety measures are indicated herein or that additional measures may be required. The user, therefore, must assume full responsibility, both as to persons and as to property, for the use of these materials including any use which might be covered by patent.

Table 1. Approved drugs for removal of internal parasites from pigs. A ✓ indicates the drug removes 90+ % of adult worms.\*

Parasite	Dichlorvos	Fenbendazole	Levamisole	Ivermectin	Pyrantel Tartrate	Piperazine	Thiabendazole
Roundworm <i>Ascaris suum</i>	✓	✓ **	✓	✓	✓ ***	✓	
Nodular worms <i>Oesophagostomum spp.</i>	✓	✓	✓	✓	✓	✓	
Whipworm <i>Trichuris suis</i>	✓	✓ **					
Lung worms <i>Metastrongylus spp.</i>		✓	✓	✓			
Red stomach worm <i>Hyostromylus rubidus</i>		✓		✓			
Threadworm <i>Strongyloides ransomi</i>			✓	✓			✓
Kidney worm <i>Stephanurus dentatus</i>		✓ **	✓	✓ **			

\* Hygromycin is not included since it is a feed additive used as a prophylactic.

\*\* Also effective against immature stages.

\*\*\* Prevents ascarid larval migration by killing the larvae as they hatch from ingested embryonated eggs.

